



Yale University School of Medicine

Reproductive and Placental Research Unit
Department of Obstetrics and Gynecology
333 Cedar Street, 312 FMB
New Haven, Connecticut 06520-8063
203 785-3854, 203 785-7642 (lab)
203 785-4477 (Fax); 203 387-6422 (Home Fax)
Text pager: 800 347-2574, PIN: 83369
http://info.med.yale.edu/obgyn/kliman
harvey.kliman@yale.edu

Harvey J. Kliman, M.D., Ph.D.

5/5/2001

Via Fax: 555-555-1212 and First Class Mail

John Smith, M.D.
General Reproductive Services
111 Anyplace Street
Anywhere, US 11111

Re: Jane Doe, Bx#: K01-003

Dear Dr. Smith,

We have completed our Endometrial Function Test (EFT) analysis of your patient’s natural cycle biopsy that we received on **2/13/2001**. Please find below the EFT results of our studies:

Stated Clinical Date: **23** Cycle day by LH surge (d13): **23** Cycle day by P (P start = d14):

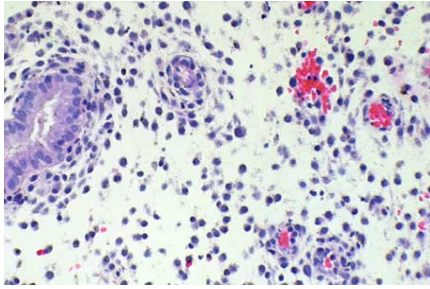
Histologic Dating

Overall Date: **24-25**
Gland Date: **19-20**
% Glands at Date: **50**
Dating comments: Significant glandular-stromal dyssynchrony, with increased glandular secretions.
Patient’s BMI: 20.0

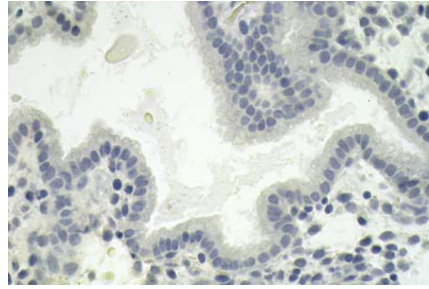
Endometrial Function Test (EFT) Panel

1° Antibody	Result	% Glands MAG Positive	Gland Cytoplasm	Gland Nuclei	Comment
A	pos				
B	neg				
O	pos				
PR	neg		0	0	Normal for histologic dating.
C30	pos	15			Moderately increased for histologic dating.
CycE	pos		3	80	Markedly increased for histologic dating.
p27	pos		0	60	Normal for histologic dating.

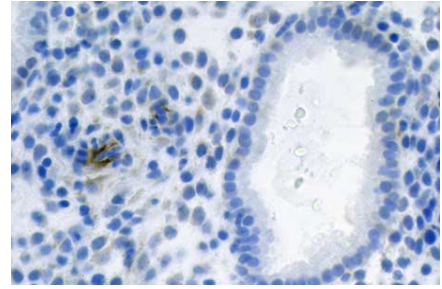
Control and Patient Photomicrographs



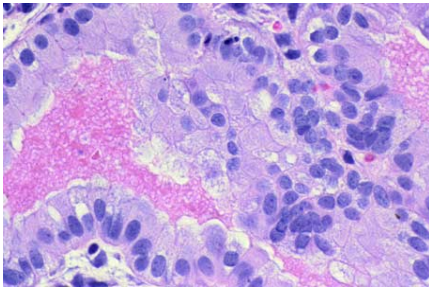
HE Control



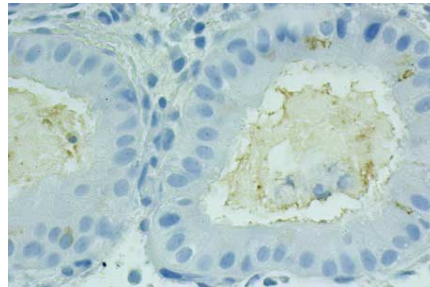
MAG Control



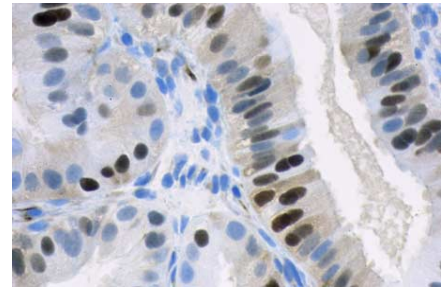
Cyclin E Control



Patient's HE



Patient's MAG or Other Image



Patient's Cyclin E

The top row of images are cycle day specific controls for standard HE staining (left), MAG reactivity (center) and cyclin E (right). The bottom row of images are from our studies of your patient. Representative areas have been chosen and may not reflect all aspects of our findings. Please note that patients who are not blood group A or AB will not have a MAG image in the above results. If warranted, other images—which will be described below—may be found in the middle bottom row. Please refer to the table on the first page, as well as the narrative comments below, for our interpretation of these results.

Interpretation

Histologically the stroma of this biopsy is two days advanced and there is significant glandular-stromal dyssynchrony with enlarged eosinophilic glands that contain excessive secretions for this time of the cycle. In addition, MAG and cyclin E are inappropriately elevated for this time of the cycle, suggesting clinically significant glandular developmental arrest (GDA), which can be caused by either inadequate estrogen priming and/or too rapid P exposure. It is of note that p27 was elevated in the first biopsy, a sign of premature progesterone action.

Thank you for allowing us to examine this endometrial biopsy and add these results to our growing research database. Please feel free to contact me if you have any questions or comments related to the above results.

Sincerely,

Harvey Kliman, M.D., Ph.D.